

# Flossing

VOL. 11

## Case Review

Proven Long-Term Stability with CeraSeal - 4 to 7y follow up cases

Clinical Snapshot of CeraSeal : Rapid Healing of Periapical Lesions

Immunity & Bioactivity Symphony - 1y follow up of CeraSeal

CeraPutty Insights : Mastering Complex Scenarios

## Events Q2, 2026

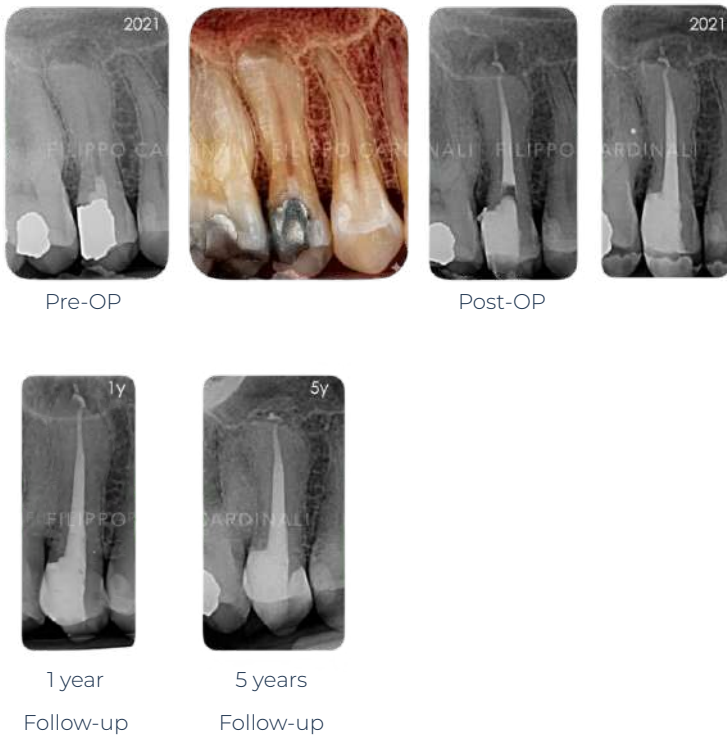## Next UP

Upcoming Key Events



# Proven Long-Term Stability with CeraSeal

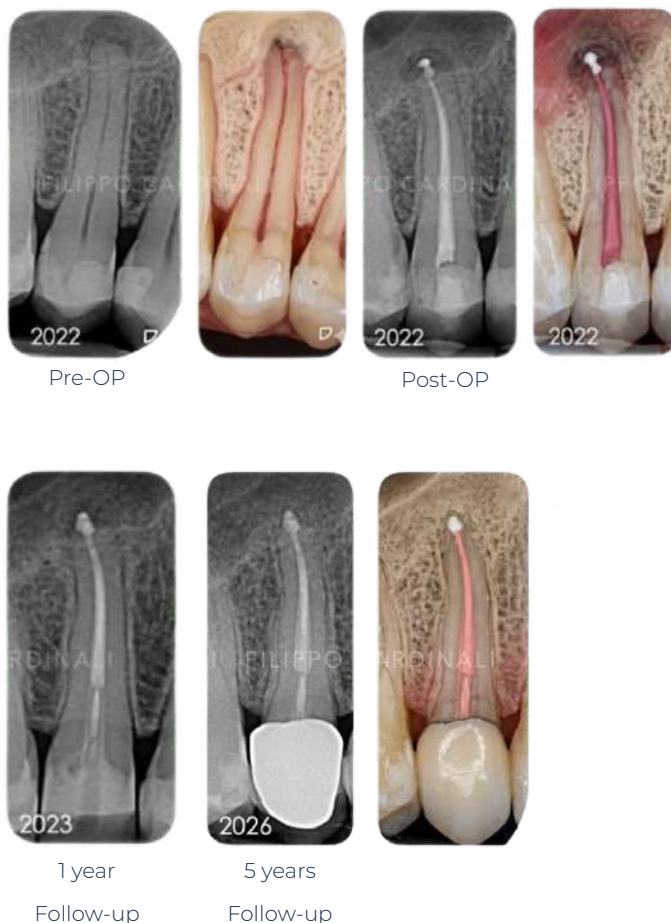## 4 to 7-Year Follow-up cases



### 1.5 Lesion - Single Visit - Overfilling - 5 years recall

Patient was referred for the treatment of a symptomatic 1.5 with that present a periapical lesion in the preoperative radiograph. The tooth was tender to percussion and palpation. Treatment was done in a single visit and the canal was obturated using the Cold Hydraulic Condensation Technique, a single cone with **CeraSeal** bioceramic sealer. Review at 1 and 5 years shows the stability of this sealer based technique and the healing of the lesion with no resorption of the overfilled bioceramic sealer. 📄

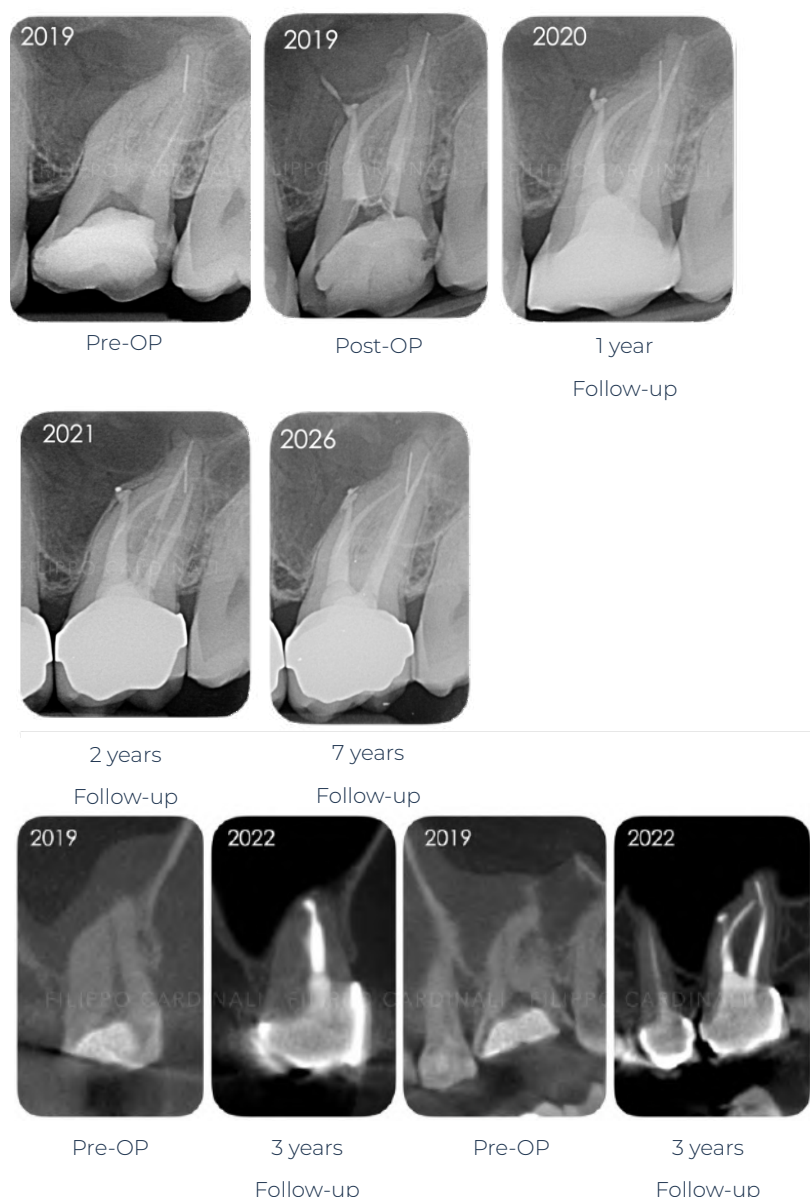
[Click to check out the full case!](#)



### 1.5: Necrosis - Periapical Lesion - CHC & CeraSeal - 4 years recall

The patient was referred for the treatment of a symptomatic 1.5, which presented a periapical lesion on the preoperative radiograph. The tooth was tender to percussion and palpation. Treatment was completed in two visits: during the first visit, the tooth was shaped, cleaned, and dressed with calcium hydroxide. During the second visit, the canal was obturated using the Cold Hydraulic Condensation technique, employing a single cone with **CeraSeal** bioceramic sealer. Follow-ups at 1 and 4 years demonstrate the stability of this sealer-based technique and the healing of the lesion, with no resorption of the overfilled bioceramic sealer. Do you want to know more about outcome of teeth with Apical Periodontitis? Check the link in the first comment and download the paper!!!! 📄

[Click to check out the full case!](#)



## 2.6 Small Perforation Management - Overfilling - 7 years recall

Patient was referred for the treatment of a symptomatic 2.6 still symptomatic after the first visit done by the referral dentist. The tooth was tender to percussion and palpation. The colleague thought the problem was the broken file in disto-buccal canal. The CBCT shows the mucosal thickening of the Schneiderian membrane of the maxillary sinus and presence of a small perforation that is probably the result of a ledge creation in the mesio-buccal canal. The maxillary sinus is tender to the palpation, the tooth was tender to percussion and palpation. Treatment was done in 2 visits. During the first visit the tooth was shaped, cleaned and dressed with calcium hydroxide. The broken file was behind the curvature and not visible under the scope; for this reason the removal was excluded and an attempt of by-pass was done. The small perforation was treated as a big canal and it was prepared up to 50 with rotary files. During the second visit the canals were obturated using the Cold Hydraulic Condensation Technique, a single cone with **CeraSeal** bioceramic sealer. The by-pass of the broken file was not successful and even the perforation was obturated with a single cone and **CeraSeal**.

At the post operative RX is visible that the overfilled material behind the perforation has a strange shape: immediately after the "foramen" of the perforation is normal as in many other cases, but the then is like a line, probably at that level there was a sinus tract inside the maxillary sinus.

Review at 1, 2, 3 and 7 years shows the stability of this sealer based technique and the healing of the lesion with no resorption of the overfilled bioceramic sealer in contact with bone structure; as expected the sealer in the sinus tract disappeared together with the infection of Schneider membrane. 🦷

[Click to check out the full case!](#)

### Dr. Filippo Cardinali (Italy)

Graduated summa cum laude in Dentistry in 1992. Active Member and Vice President of the Italian Society of Endodontics. Certified Member of the European Society of Endodontology. Associate Member American Association of Endodontists. Gold Member of Style italiano Endodontics. Private practice, concentrating mainly in Endodontics and Restorative Dentistry, author of publications on journals of national and international sector, speaker at national and international congresses and workshops.

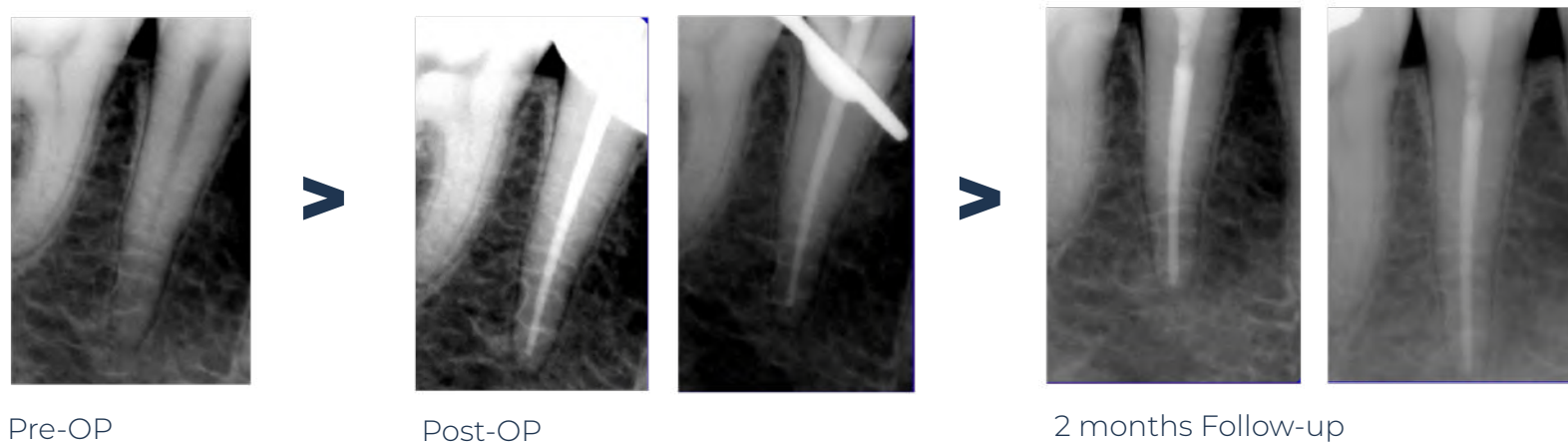
**Instagram** @cardinali\_endodontics

**Facebook** @filippo.cardinali.5



# Clinical Snapshot of CeraSeal: Rapid Healing of Periapical Lesions

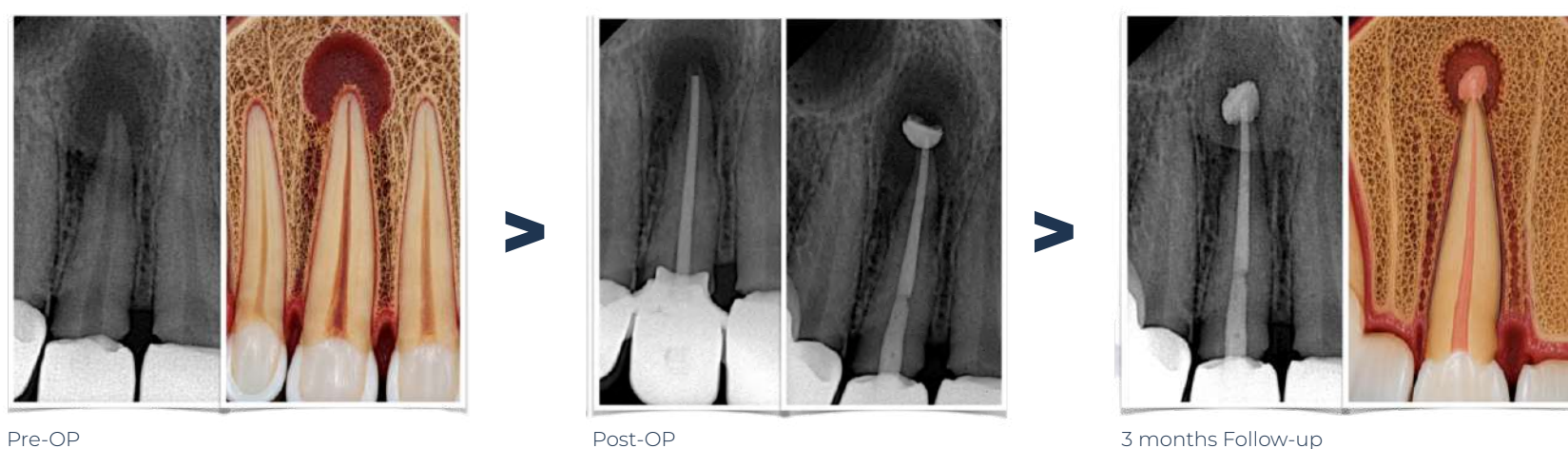- RCT of Lower Right Second Premolar



Lower premolar with small periapical lesion demonstrating rapid and complete resolution within 2 months, attributed to the bioactivity and biocompatibility of **CeraSeal** bioceramic sealer... 🦷

[Click to check out the full case!](#)

- RCT of Upper Right Lateral Incisor

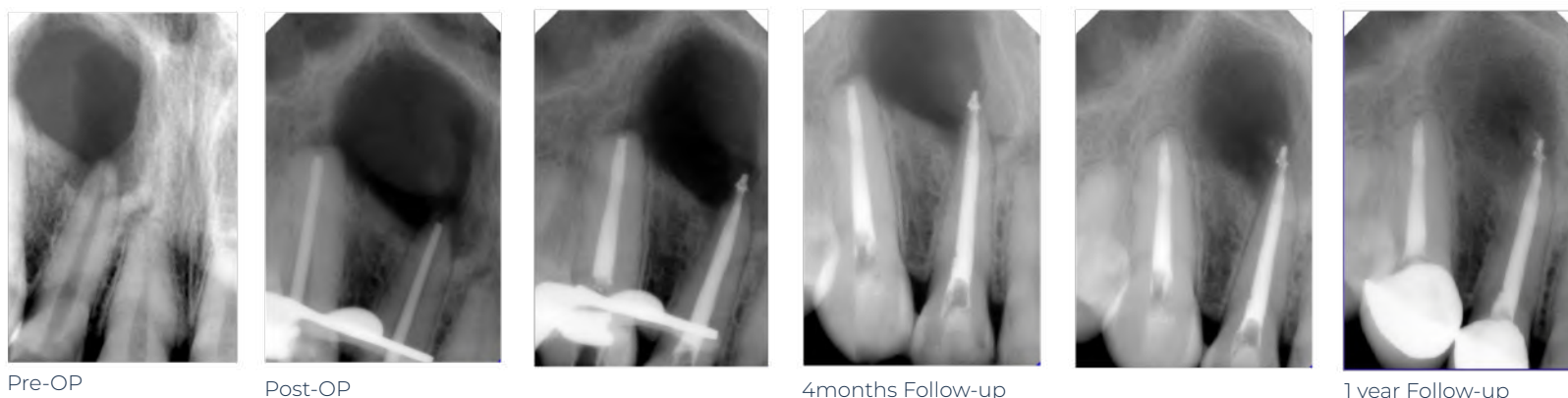


Upper lateral incisor with large periapical lesion demonstrating rapid healing, bone formation within 3 months, attributed to the bioactivity and biocompatibility of **CeraSeal** bioceramic sealer. The material remained stable & non-resorbed even in challenging environment. 🦷

[Click to check out the full case!](#)

# Immunity & Bioactivity Symphony!!

## 1 year Follow-up case of CeraSeal



Root canal treatment was performed on the maxillary right lateral incisor and canine. Preoperative CBCT imaging revealed a large periapical lesion associated with both roots, accompanied by extensive surrounding bone loss. Although extraction had initially been proposed as the treatment of choice, the patient declined surgical intervention.

### “CeraSeal as a Cornerstone to achieve 3D Obturation”

A conservative orthograde endodontic approach was therefore undertaken, with a structured plan for periodic clinical and radiographic reassessment to evaluate healing progression.

Following thorough chemomechanical preparation, obturation was completed using **CeraSeal** bioceramic sealer in continuous wave of compaction (CWC) technique. This approach ensured optimal three-dimensional sealing of the root canal system, supporting both disinfection and long-term biological repair.

### “Radiographic evidence of remarkable Healing”

At the 4-month follow-up, radiographic evaluation demonstrated early signs of healing, characterized by peripheral bone formation surrounding the lesion and at the apical regions of both teeth.

The patient was subsequently scheduled for a 1-year follow-up to enable close monitoring and to detect any potential relapse. The favorable response observed within this relatively short interval may be attributed to a combination of factors, including the patient’s age, an effective host immune response, and the bioactive properties of **CeraSeal** bioceramic sealer. This noticeable reduction in lesion size, with evident progressive bone regeneration indicate ongoing healing, although continued follow-up is essential to confirm complete resolution and long-term stability of the treatment outcome. 🦷



### Dr. Mostafa Anwar (Egypt)

Graduated from Ain Shams University, Egypt. Diploma of Healthcare & Hospital Management from the American University in Cairo. Master Degree of Endodontics from Ain Shams University on June 2015 & PhD Researcher. International Dental Conferences & Endodontics Key Opinion Leader. Co-Author of Retreatments by SIE. Micro-Endodontics Specialist at private practice, Cairo and the Gulf area.

[Instagram](#) @mostafa\_anwar [facebook](#) @Mostafa Anwar

# CeraPutty Insights : Mastering Complex Scenarios

## Non surgical Retreatment of Two Maxillary Central Incisors with Open Apices and Extruded Gutta Percha

### Pre-operative Assessment and Diagnostic Interpretation

Both maxillary central incisors presented with previous endodontic treatment and compromised apical limits.

The previous root canal fillings were inadequate in relation to the open apical anatomy, with gutta percha extending beyond the radiographic apices.

The apical anatomy showed absence of a predictable natural constriction, indicating that conventional apical stop preparation would be inappropriate.

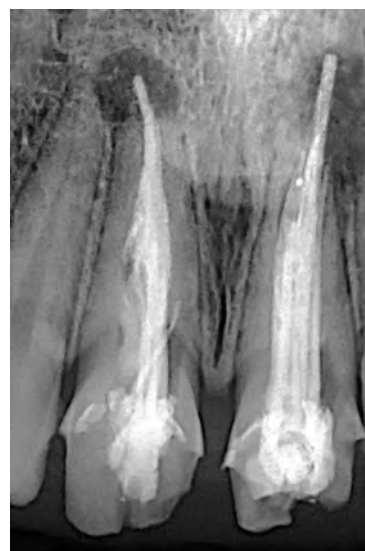
The periapical findings were consistent with persistent apical periodontitis associated with infected canal spaces. The treatment plan prioritized preservation of apical dentin, prevention of additional apical irritation, and creation of a controlled terminal barrier.

### Clinical diagnosis

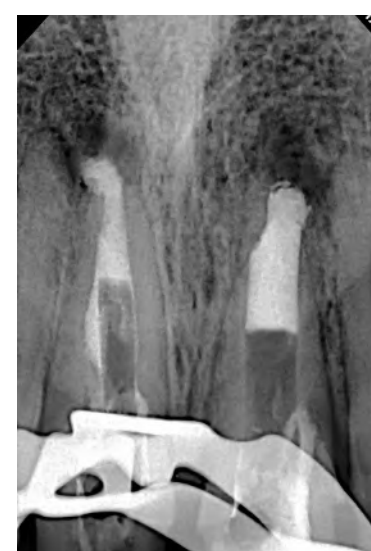Previously treated maxillary central incisors with persistent apical periodontitis. Open apices with loss of an apical stop. Extruded gutta percha requiring controlled retrieval through the canal rather than apical pushing or aggressive over-instrumentation.

### Treatment objectives

Remove the previous root canal filling material while maintaining control of the apical anatomy. Retrieve the overextended gutta percha by controlled coronal traction through the canal space. Disinfect the canal system with a protocol adapted to infected teeth with open apices. Create a stable apical barrier using **CeraPutty** bioceramic repair material. Complete the root canal filling and reinforce the coronal structure with fiber posts. Monitor periapical repair over time.



Pre-OP



CeraPutty apical plugs

### Retreatment Strategy: Controlled removal and Infection Control

The retreatment phase was designed to eliminate contaminated filling material while avoiding removal of too much canal dentin, debris extrusion, and unnecessary enlargement of the open apices. The operative objective was controlled debridement, not aggressive apical enlargement.

### Retreatment sequence

Rubber dam isolation and access refinement were performed to obtain direct access to both canals. The coronal and middle portions of the previous gutta percha fillings were removed first to create a controlled pathway toward the apical segments. The apically extruded gutta percha portions were engaged from within the canal and withdrawn coronally. Working length and apical limits were reassessed during the procedure because of the open apex teeth lack a reliable apical constriction.

### Chemical disinfection sequence

Irrigation was performed with a side vented needle positioned short of the apical terminus and kept loose inside the canal. Sodium hypochlorite 3% was delivered to maximize antimicrobial activity while reducing the risk of extrusion through the open apex. Irrigant activation was used to improve exchange within the apical third, canal irregularities, and surfaces previously occupied by infected filling material. EDTA 17% solution included to remove the smear layer and improve cleanliness of the dentinal walls before apical barrier placement. Activation to irrigant done by using passive ultrasonic activation and Intracanal heating to Sodium Hypochlorite. The canals were dried with micro aspirator.

### CeraPutty Apical Barrier Formation

**CeraPutty** bioceramic repair material from Meta Biomed was used to establish apical plugs in both central incisors. The placement protocol was performed through incremental delivery, controlled adaptation, and radiographic verification before final obturation.

### Stepwise placement protocol

The canals were dried while maintaining a dentinal environment compatible with bioceramic hydration and setting. A premeasured plugger was selected to fit passively within the canal and to terminate short of the apical limit.

**CeraPutty** was introduced into the apical third in small increments using MAP system. Each increment was carried apically and adapted with controlled vertical pressure, avoiding forceful compaction through the open apex.

The increments were condensed to form a dense apical plug with clinically adequate thickness. Radiographic verification was performed to confirm the position, thickness, and adaptation of the plug against the apical walls. After confirmation of the apical barriers, the remaining canal space was obturated coronally with fiber post placement as required and recommended by prosthodontist.

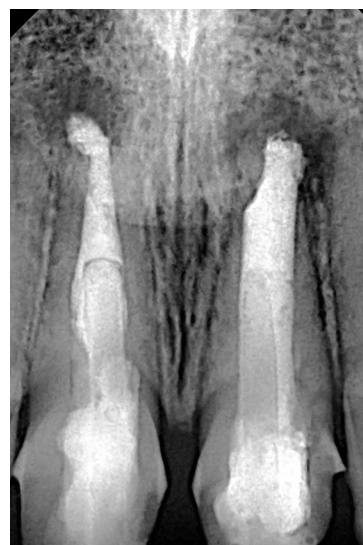### Biological rationale

The apical plug provides a controlled terminal barrier in teeth lacking a natural apical stop. The barrier reduces the risk of overextension during the final obturation phase. Bioceramic repair materials are clinically useful in this situation because they can adapt to irregular apical anatomy and set in a moist environment.

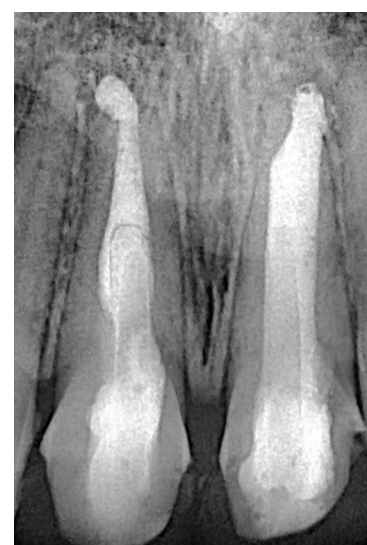Radiographic verification before completing the obturation is essential because correction becomes more difficult after the canal is filled coronally. Bioceramic repair materials are clinically useful in this situation because they can adapt to irregular apical anatomy and set in a moist environment. Radiographic verification before completing the obturation is essential because correction becomes more difficult after the canal is filled coronally.

### Two-year follow-up interpretation

The follow up radiograph demonstrated favorable periapical repair around both incisors with complete healing. The apical barriers remained stable with no radiographic evidence of displacement. The periapical bone pattern showed increased radiographic density compared with the pre operative condition. No progressive inflammatory change was evident at the follow up stage. The outcome reflects the combined effect of controlled retreatment, chemical disinfection, stable apical barrier formation, and coronal reinforcement.




Post-OP



2 years follow up

### Conclusion

This case demonstrates a biologically driven approach to retreatment of maxillary central incisors with open apices and extruded gutta percha. The outcome depended on controlled removal of the extruded filling material, chemical disinfection of the infected canal spaces, precise **CeraPutty** apical plug application, and coronal reinforcement. The two years follow up demonstrated favorable periapical repair and stable apical barrier behavior. 

# Broken File Retrieval and Pulpal Floor Perforation Repair

## Clinical presentation

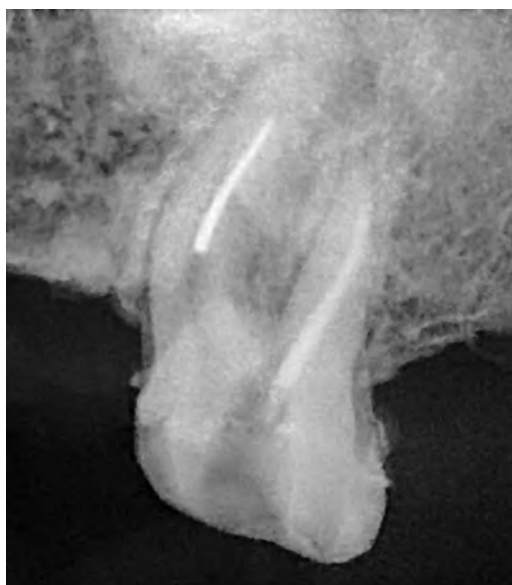A 45 year old male patient presented with a complicated endodontic situation. After rubber dam isolation and magnification assisted inspection, the access cavity revealed a compromised pulp chamber. A separated instrument was visible in the canal entrance area, and a pulpal floor perforation was identified adjacent to the chamber floor. The clinical challenge was to manage the separated instrument while preserving the remaining tooth structure, then complete the endodontic treatment and repair the perforation in a controlled sequence.

## Clinical diagnosis

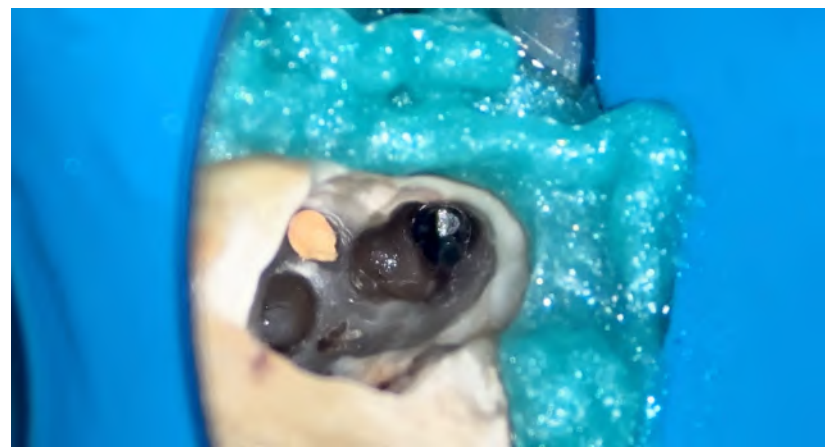
Previously treated tooth with CAP  
Complicated endodontic case involving a separated instrument, pulpal floor perforation, compromised chamber floor anatomy, and the need for conservative retrieval followed by canal treatment and bio-ceramic perforation repair.

## Treatment sequence

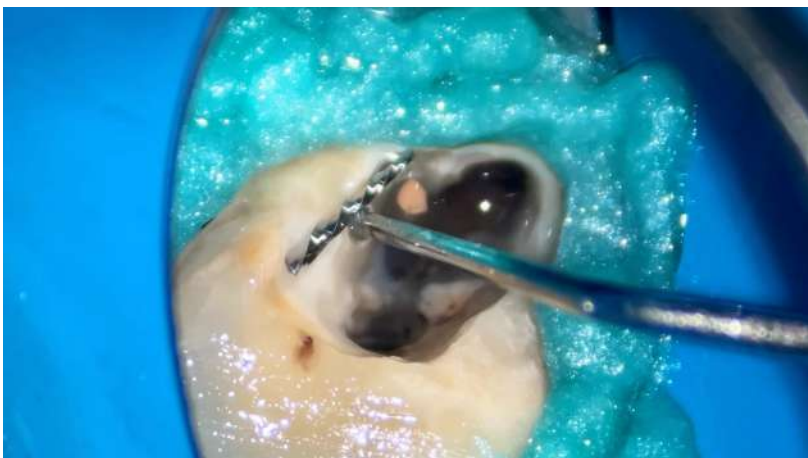The tooth was isolated with rubber dam and the operative field was assessed under magnification. Access refinement and chamber cleaning were performed to improve visibility and allow controlled management of the separated instrument. Ultrasonics were used conservatively around the coronal part of the fragment to loosen its engagement while minimizing unnecessary dentin removal. The separated instrument was successfully retrieved.



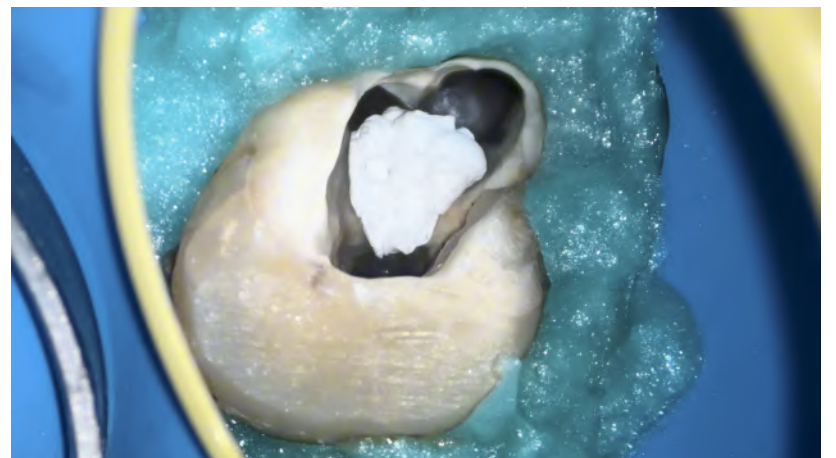
Pre-OP



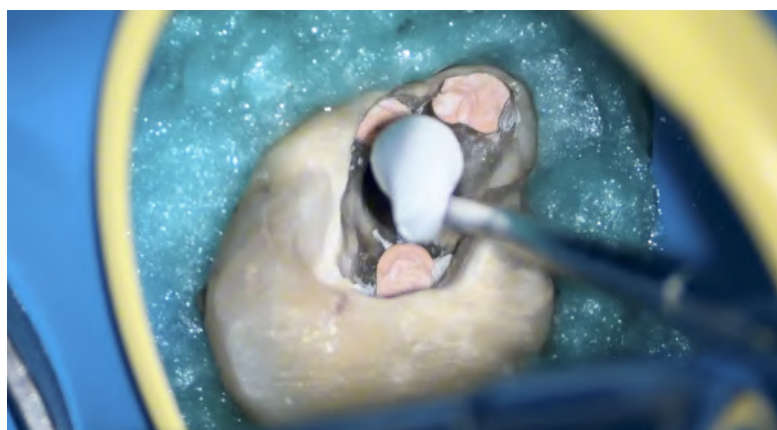
Broken file and floor perforation



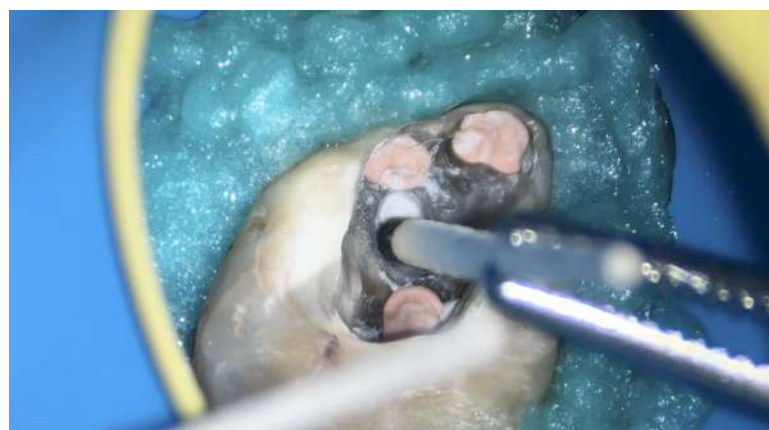Retrieval by ultrasonics



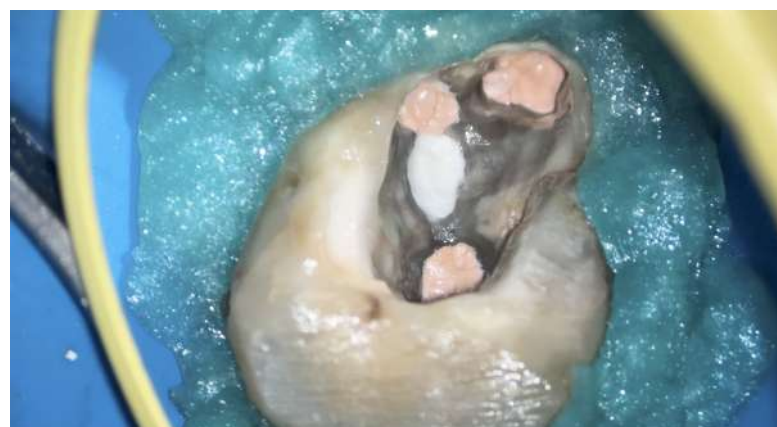protection to perforation site during obturation



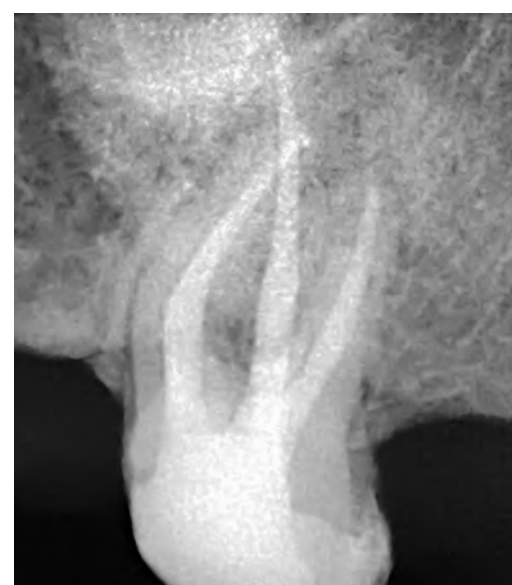CeraPutty application



CeraPutty adaptation to perforation site



Treatment completed



Post-OP

### Canal management and obturation

After retrieval, canal negotiation was completed. The canals were cleaned, shaped, and chemically disinfected according to the needs of an infected complicated endodontic case. Before obturation, the perforation site was protected using sterile Teflon. This protection isolated the perforation area during obturation and prevented contamination or blockage of the defect by obturation materials. The canals were then obturated while the perforation site remained protected.

### Perforation repair

After completion of the obturation phase, the sterile Teflon was removed. The pulpal floor perforation was then repaired using **CeraPutty** bioceramic repair material. The material was delivered directly to the perforation site and gently adapted to the margins of the defect to achieve a stable seal while preserving the completed obturation and the surrounding chamber anatomy. 🦷

### Dr. Mohamad Zaafarny (Egypt)



Graduated from Mansoura University, Egypt (2003). Lecturer in the International Endodontic Diploma at Jaume I University, Spain. Diamond Member of Style Italiano Endodontics & Digital Smile Design (DSD) team. International Dental Conferences Speaker & Endodontics Key Opinion Leader. Co-Author of "Retreatments" by SIE. Winner of Best Endodontic Case worldwide (2016) & AEEDC Dubai Best Speaker (2023). Head of the Endodontic Department at Hala Dental Center, Mansoura.

**Instagram** @mohamed\_elzaafarani

**Facebook** @mohammed.zafrany

# The Synergy of Bioceramics : IDEX Istanbul 2026

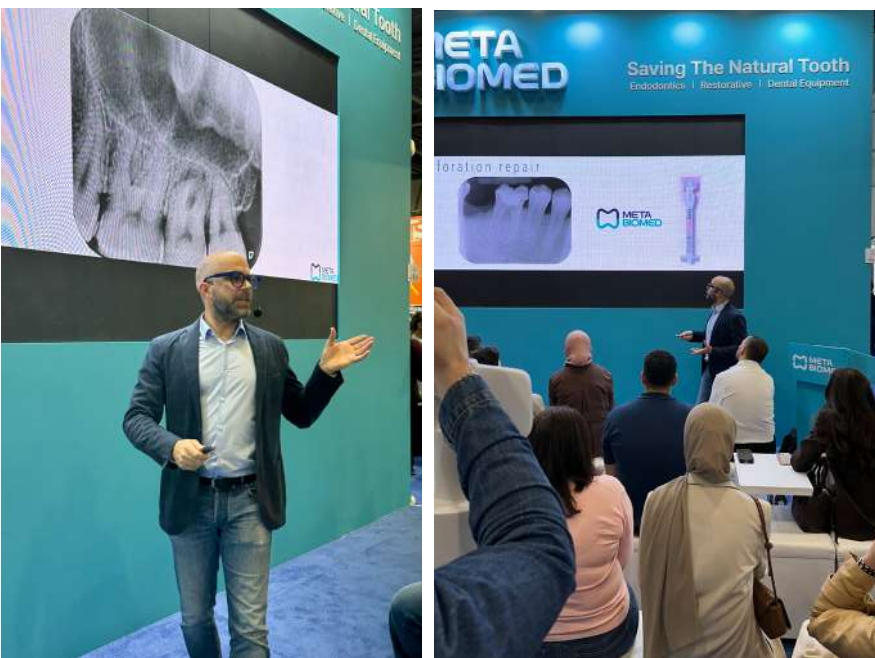


Meta Biomed participated in IDEX Istanbul 2026 in Türkiye. During the exhibition, we held special booth lectures under the theme, “*The Synergy of Bioceramics – CeraSeal & CeraPutty*,” which attracted a large number of dental professionals and visitors.

On April 16, Dr. Mostafa Anwar presented “*Hacking the Bioceramics in Endodontics: CeraSeal and CeraPutty in Practice.*” He conducted two 60-minute sessions. In these lectures, he explained the biological and physical advantages of these materials, including bioactivity, biocompatibility, and superior sealing. He demonstrated practical techniques for predictable 3D obturation, managing perforations and open apex cases, and promoting periapical healing. Attendees gained actionable strategies to simplify procedures, evaluate obturation quality clinically and with CBCT, and achieve long-term endodontic success.



▲ Lecture by Dr. Mostafa Anwar

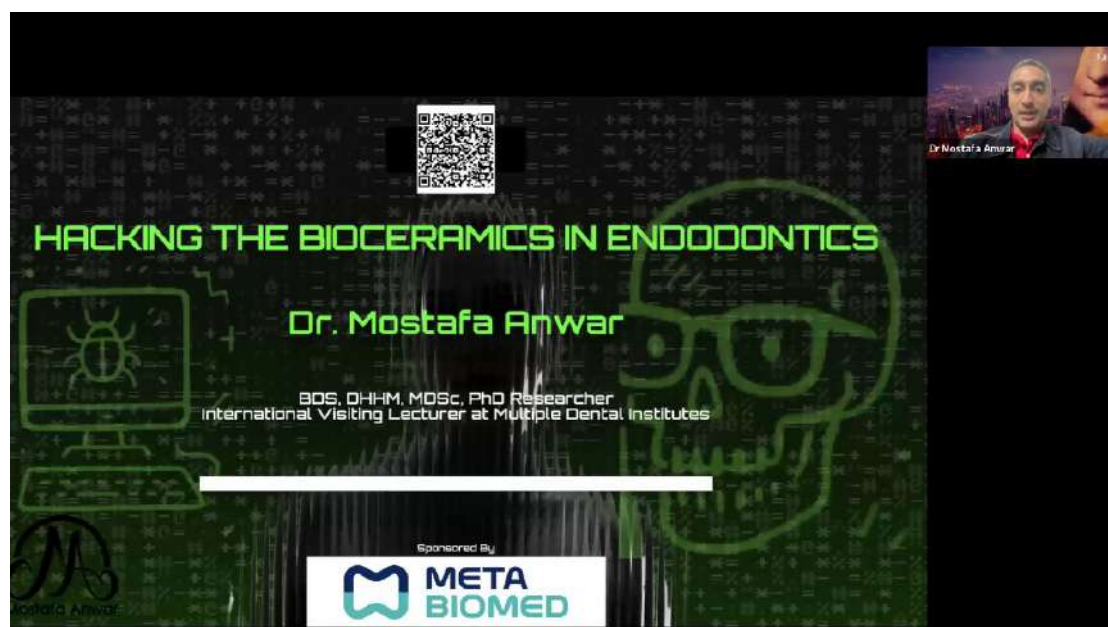
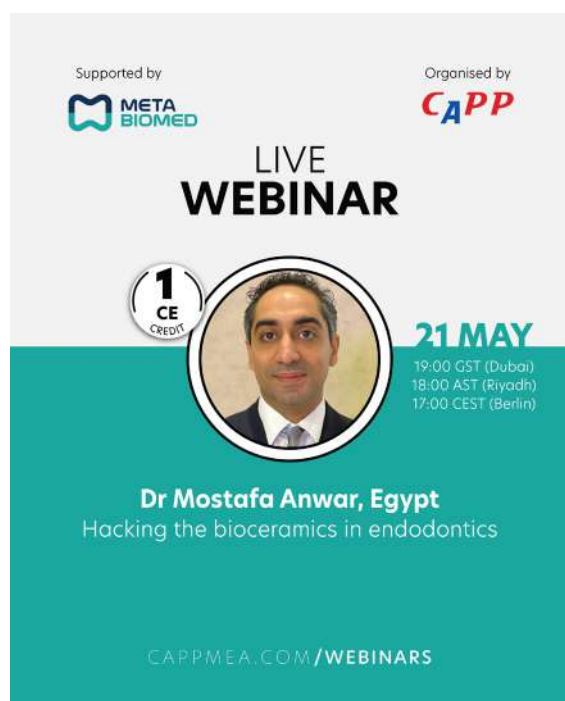

▲ Lecture by Dr. Claudio Farnararo

On April 17, Dr. Claudio Farnararo from Italy delivered his lecture, “*Bioceramic Materials in Endodontics; From Sealers to Putty – Clinical Applications of CeraSeal and CeraPutty.*” He also conducted two 60-minute sessions. In these lectures, he shared clear, evidence-based guidelines for everyday practice, covering proper indications, limitations, material handling, and specific obturation techniques. His sessions offered expert tips for successful treatment and retreatment to help clinicians achieve more predictable results in root canal treatments, perforation repairs, and apical surgeries. Thank you to all the visitors and dental professionals who connected with Meta Biomed at IDEX Istanbul 2026. We appreciate your support and look forward to welcoming you back at IDEX Istanbul 2027! 🦷

# Meta Biomed X **CAPP**

## Successful Live Webinar with Dr. Mostafa Anwar



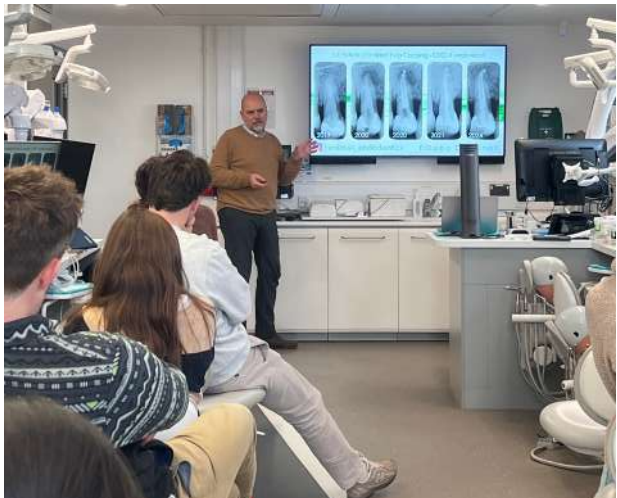CAPP hosted a Live Webinar featuring *Dr. Mostafa Anwar*, proudly supported by Meta Biomed, which successfully drew thousands of attendees. Held on May 21 at 19:00 (GST), *Dr. Mostafa Anwar* led an insightful webinar titled, “*Hacking the bioceramics in Endodontics.*” This online event was deeply focused on expanding the knowledge of bioceramic materials for dental professionals. During the webinar, attendees learned about the key characteristics and essential understanding of bioceramic sealer ‘CeraSeal’ and bioceramic putty ‘CeraPutty’. He shared his extensive experience by presenting various clinical cases and outcomes using these products. Furthermore, he provided practical clinical know-how and tips that doctors can easily integrate into their daily practice to achieve better treatment results. We remain committed to bringing you high-quality clinical education and innovative product updates. Stay connected with us on Facebook and Instagram for more upcoming events! 📱

## The Spotlight at HAIDEC 2026 in Hanoi, Vietnam



Meta Biomed’s trusted partner in Vietnam, Viet Dang, successfully finished HAIDEC 2026 in Hanoi, held from May 12th to 14th! During the event, there was continuous interest in **CeraSeal**, leading to non-stop purchases from the visitors throughout the exhibition. There was also great interest in our bioceramic putty, **CeraPutty**, and **Jet Flow bulk**, which is a newly introduced bulk fill resin in Vietnam. Viet Dang also prepared a special promotion and a survey event, which drew active participation from the attendees. Thanks to everyone who came by to support us, and please look forward to our upcoming events! 📱

# International Endodontic Congress in Zagreb, Croatia



▲ Hands-on Training by Dr. Filippo Cardinali



▲ Lecture by Dr. Filippo Cardinali



Meta Biomed Europe (The Europe team) participated in the International Endodontic Congress in Zagreb, Croatia, which took place on May 9. During the congress, the Europe team operated a dedicated exhibition booth to showcase our products. In addition to the exhibition, *Dr. Filippo Cardinali* delivered an insightful lecture during the event, sharing valuable clinical knowledge with the audience. As one of Croatia's leading international endodontic conferences, this event brought together renowned experts and dental professionals from around the world. The congress provided a great platform to discuss the latest developments, clinical approaches, and innovations in endodontic treatment and vital pulp therapy. The Europe team is deeply grateful to *Dr. Filippo Cardinali* and all the attendees who visited our booth and joined the lecture. Please stay tuned for the Europe team's upcoming events! 📩

## SIDEX 2026 Highlights: Exclusive Offers in Seoul, Korea

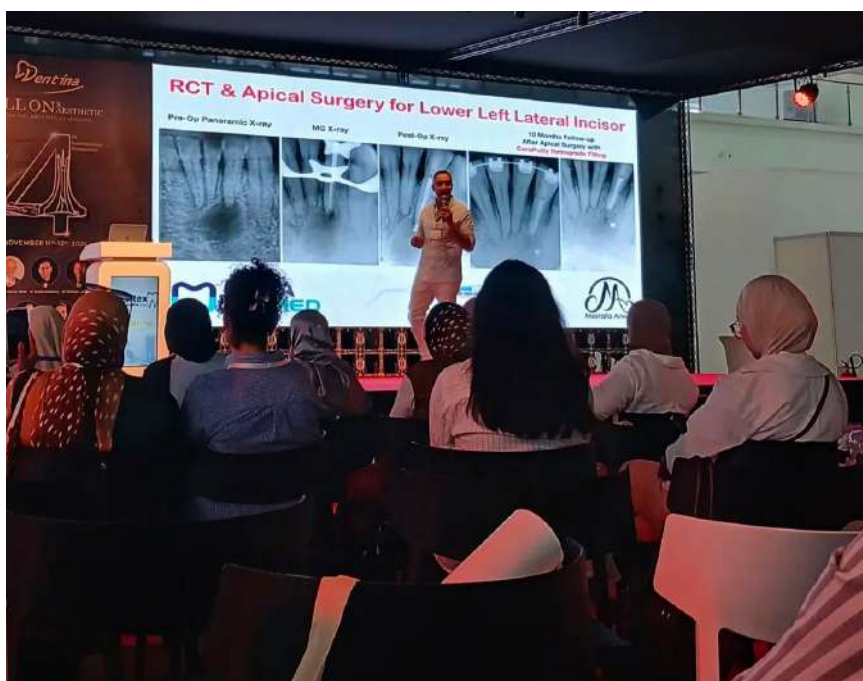

At SIDEX 2026, held at COEX from May 29 to 31, Meta Biomed successfully showcased its dental products at booth C-737, connecting with dental professionals from around the globe. Our special promotions completely sold out our prepared stock, generating particularly high interest in our bioceramic putty, '**CeraPutty**'. We also provided hands-on opportunities for both '**CeraPutty**' and '**Jet Flow bulk**' allowing visitors to experience their exceptional handling and efficiency firsthand. Furthermore, we had a highly meaningful time engaging directly with clinicians to exchange valuable feedback and insights about our products.

Furthermore, we introduced our new shade-matching device, which measures tooth shade. Instead of just leaving it on display, we let visitors try it out right at the booth and see the readings on the spot. Visitors also had the chance to personally handle and test our products, including **CeraSeal** and **CeraPutty**. We sincerely thank everyone who visited the Meta Biomed booth at SIDEX 2026 and look forward to seeing you again at HO-DEX 2026. 📩



# DENTINA Captures All Eyes at DENTEX 2026 with Bioceramics



▲ Lecture by Dr. Mostafa Anwar



At DENTEX 2026 in Algeria, the exclusive local distributor DENTINA participated with a dedicated exhibition booth. A key highlight of the event was the educational sessions led by *Dr. Mostafa Anwar*, a Key Opinion Leader (KOL) for Meta Biomed, which drew a large audience of dental professionals to the booth. *Dr. Mostafa Anwar* conducted two specialized lecture sessions at the DENTINA booth titled "*HACKING THE BIOCERAMICS IN ENDODONTICS*". During these sessions, he demonstrated the clinical applications of the bioceramic sealer *CeraSeal* and the premixed putty *CeraPutty*. Additionally, on June 3rd, he delivered a main conference lecture titled "*BIOCERAMICS IN ACTION: TRANSFORMING OUTCOMES*", focused on the integration of bioceramic protocols in endodontic treatments.

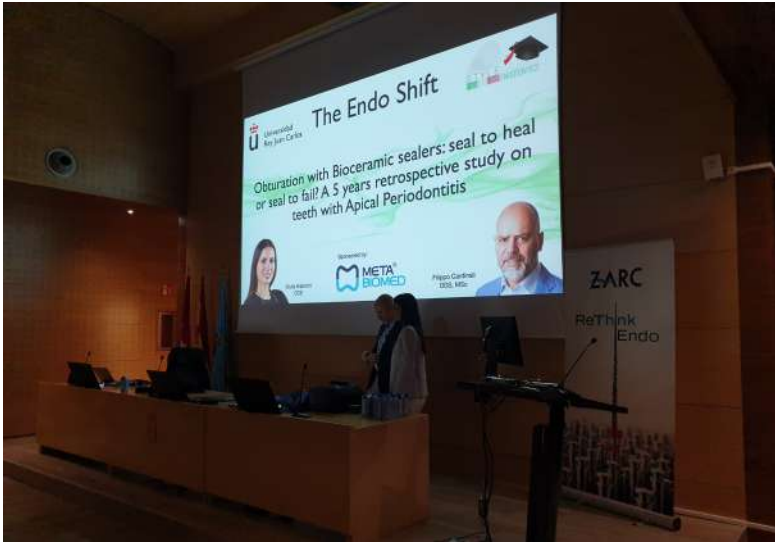

▲ Hands-on Training by Dr. Mostafa Anwar



Following the presentations, *Dr. Mostafa Anwar* hosted a practical hands-on course. This session allowed participating Algerian clinicians to directly test the handling, flowability, and sealing performance of both *CeraSeal* and *CeraPutty*. The hands-on training concluded with positive feedback from the participants, successfully demonstrating Meta Biomed's endodontic solutions through DENTINA's local platform. Meta Biomed deeply appreciates the hard work of its exclusive partner DENTINA and the outstanding contribution of *Dr. Mostafa Anwar* at DENTEX 2026. 🇩🇪

# The Endo Shift at Rey Juan Carlos University



▲ Lecture by Dr. Filippo Cardinali & Dr. Giulia Malvicini



Meta Biomed Europe (The Europe team) was proud to sponsor The Endo Shift – Style Italiano Campus Project Madrid 2026. June 12th was a truly meaningful day for us. The Europe team had the privilege of supporting the outstanding lectures by *Dr. Filippo Cardinali* and *Dr. Giulia Malvicini*, who brought together clinicians to explore a question at the heart of everyday practice: *“Obturation with bioceramic sealers: Seal to heal or seal to fail? A 5-year retrospective perspective on outcomes in teeth with apical periodontitis.”* Drawing on real clinical data, both speakers shared valuable insights that left a lasting impression on everyone in the room. Inspired by the lecture, a great number of SIE members and visitors stopped by the Meta Biomed booth throughout the day. There, The Europe team was delighted to showcase our bioceramic sealer, **CeraSeal**, and to connect face-to-face with dental professionals. Proud of our Europe team for making this event a huge success. Let’s keep moving forward! 🗨️

## Scenes from SINO Dental 2026 in Beijing, China

From June 9 to 12, Meta Biomed China joined the 30th Sino-Dental 2026 at the China National Convention Center (CNCC) in Beijing, actively promoting its main products and hosting busy hands-on sessions at the booth. Located right at the entrance of the Korean Pavilion in Hall 1 (Booth K56, K58), Meta Biomed China welcomed many visitors who were looking for high-quality Korean dental products. Attendees had the opportunity to experience our hydraulic condensation concept using **CeraSeal**, **EQ-V**, and **Gutta Percha Points**, followed by product consultations. Moving forward, Meta Biomed China plans to host local lectures and hands-on courses with a local KOL, Dr. Kang Yu. We will also participate in DenTech China 2026 in Shanghai this October to continue promoting our brand and product value. 🗨️





## MASTERING BIOCERAMIC APPLICATIONS: CLINICAL SCENARIOS

**Overview :**

- แนวคิดและหลักการของ **Bioceramic Sealer**
- เทคนิค **3D Obturation** ด้วย **Hydraulic Calcium Silicate**
- การประยุกต์ใช้ **Bioceramic Putty** ในเคสซับซ้อน เช่น **Perforation, Open Apex, Internal Resorption**

📅 27 กันยายน 2569  
🕒 09:45 - 15:30 น.  
📍 The Sukosol Hotel, Bangkok (Rattanakosin Room, 1st Floor)



ลงทะเบียน

## Mastering Bioceramic Applications: CLINICAL SCENARIOS

**Program Schedule:**

09:45 - 10:00	Welcome & Registration
10:00 - 11:30	Session 1: Bioceramics in Endodontics
11:30 - 12:15	Session 2: Bioceramics Putty Evolution & Clinical Applications - Part 1
12:15 - 13:00	Lunch Break
13:00 - 14:30	Session 2: Bioceramics Putty Evolution & Clinical Applications - Part 2
14:30 - 14:45	Afternoon Break
14:45 - 15:30	Q&A and Wrap-up

📅 27 กันยายน 2569 🕒 09:45 - 15:30 น. 📍 The Sukosol Hotel, Bangkok (Rattanakosin Room, 1st Floor)

VRP Dent

@vrpdent




VRP Dent

@vrpdent




## UPCOMING KEY EVENTS 3Q, 2026

 <p><b>HODEX 2026</b> 4-5 JUL</p>	 <p><b>IDEX EGYPT 2026</b> 13-15 AUG</p>
 <p><b>INDEX 2026</b> 26 JUL</p>	 <p><b>WORLD ENDODONTIC FORUM</b> 13 AUG</p>
 <p><b>GAMEX 2026</b> 19-20 SEP</p>	 <p><b>PRISHTINA DENTAL WEEKEND</b> 18-20 SEP</p>



## WANTED!

### New Idea & Clinical Case



**We're All Ears for Your Big Ideas!**  
Share your brilliance with us and help shape FLOSSING by Meta Biomed! Your idea will be the next big thing in our upcoming editions.


**Show your BEST Clinical Cases made by CeraSeal**  
It'd be lovely if we could share your BEST CeraSeal Cases with our tons of followers all around the world. Don't lock up the amazing cases you got in the drawer. Show it off!

**For more inquiries:** [dental@meta-biomed.com](mailto:dental@meta-biomed.com)




## Stay connected with us!

Follow our SNS channels by scanning the QR code and be a part of our engaging conversations and exclusive updates.

SCAN HERE



www.meta-biomed.com

**Flossing** is a newsletter made by Meta Biomed (Dental) in 2023, which means taking out various information and delivering it to you, as if you were flossing teeth. [Click to subscribe for Free.](#)

# 환자 마음을 꿰뚫는 VPT LIVE

2026. 7. 11 SAT 16:00 - 19:00

서울대학교 치과병원 지하 1층 승산강의실 \*서울특별시 종로구 대학로 101

## PROGRAM

1 **Vital Pulp Therapy  
실전 핵심 요약**

최적의 체어타임 노하우  
성공률을 가르는 진짜배기들

2 **현미경-석선로봇-  
VPT-크라운프렘**

올인원 Live

3 **Q&A**

연자 **라성호** 원장

약력 서울대 보존과  
이촌동 서울미소치과



참가시 10만원 상당의 사은품 증정!

참가비 | 3만원 \*VAT 포함  
참가 방법 | QR 코드 스캔 후 신청  
참가 인원 | 선착순 100명

